

# Topical haemoglobin spray for chronic wound therapy

Wound oxygenation

12 ml unit =  
3 months  
treatment\*

- ✓ Time to heal diabetic foot ulcers 50% shorter than with standard of care<sup>1</sup>
- ✓ Twice as many chronic wounds healed at 8–16 weeks compared to standard of care<sup>1,2,3</sup>
- ✓ More than 70% lower average pain scores at four weeks than with standard of care in chronic wounds<sup>3</sup>
- ✓ Less slough during wound management: 99% less slough in chronic wounds after 4 weeks compared to 33% with standard of care<sup>4</sup>
- ✓ Treatment costs in diabetic foot ulcers at least 40% lower than with standard of care<sup>5</sup>



\*May vary slightly depending on wound size

Granulox®

Mölnlycke®

# Complex, stalling and chronic wounds

## Chronic wounds

A hard-to-heal wound has been defined as one that fails to heal with 'standard therapy' in an orderly and timely manner<sup>6</sup>. Irrespective of this time-based definition, wounds are classified as chronic from the outset, if they require treatment for a persistent underlying cause. This includes, for example, diabetic foot ulcers, wounds associated with peripheral artery disease, venous leg ulcers, or pressure ulcers.

The success of any treatment of chronic wounds hinges on the diagnostic determination and the causal treatment of the underlying, pathophysiologically relevant diseases.

This will include relevant psychosocial factors. In parallel, the majority of patients should receive moist wound therapy based on the various phases of wound healing.

Prevalence of chronic wounds in Germany

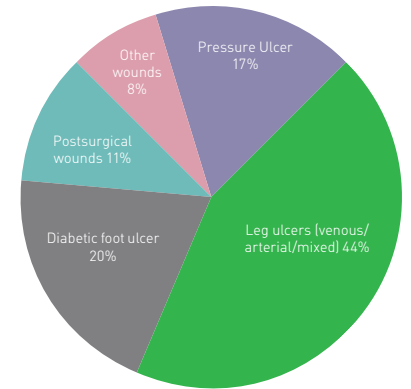
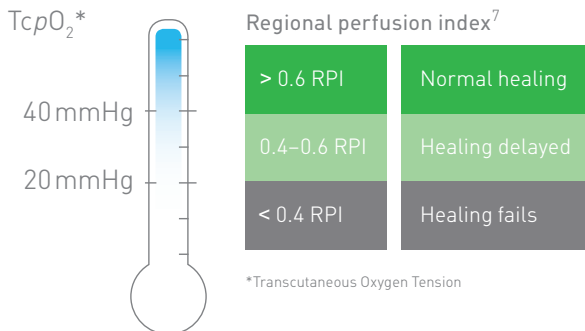


Figure: Studie Primärmedizinische Versorgung (PMV) Köln, Germany, 2016

## The importance of oxygen in wound healing

Measurement of tissue oxygenation



Oxygen plays a vital role in wound healing<sup>7</sup>. Evidence demonstrate that poorly oxygenated wounds almost never heal, while oxygenated wounds do. In a study, 97% of non-healing wounds were found to have low oxygen levels.

'In the absence of other wound healing inhibitory factors, local hypoxia is the central problem of an impaired wound healing.'

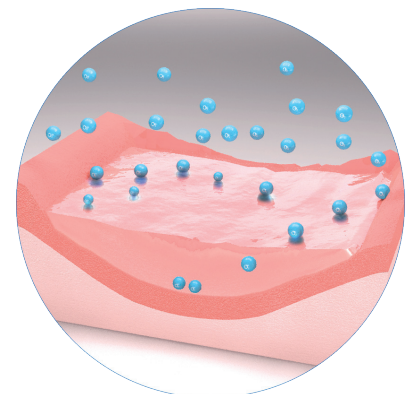
Kröger et al<sup>9</sup>.

Increased oxygen requirement, but poor oxygen supply: the need for oxygen is particularly high in all phases of wound healing because of increased metabolic activity. The underlying, primary disease (e.g. diabetes, arterial occlusive disease) leads to inadequate oxygen supply via the impaired vascular system, resulting in hypoxia in the wound area. The lack of oxygen leads to delayed healing, or in some cases even blocks any progression in healing<sup>8</sup>.

## Making oxygen available to the wound tissue

A liquid film as thin as 0.02 mm (20 micrometres) blocks 95% of un-aided oxygen diffusion<sup>10</sup>. Despite oxygen being readily available in the ambient air, diffusion to the base of the wound bed is limited by barriers such as wound exudate.

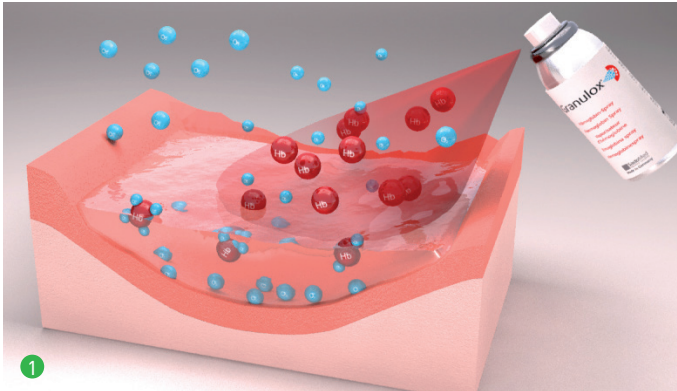
The wound healing process can be facilitated and accelerated by delivering oxygen into the wound bed to combat hypoxia<sup>8</sup>.



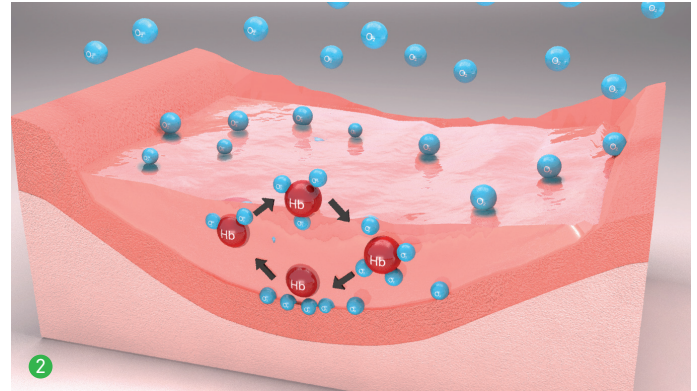
# The way it works

## Unique mode of action – Granulox® acts like a shuttle for oxygen molecules

Granulox® provides the wound with the required oxygen by means of diffusion. The active substance haemoglobin supplies the base of the wound externally with oxygen.

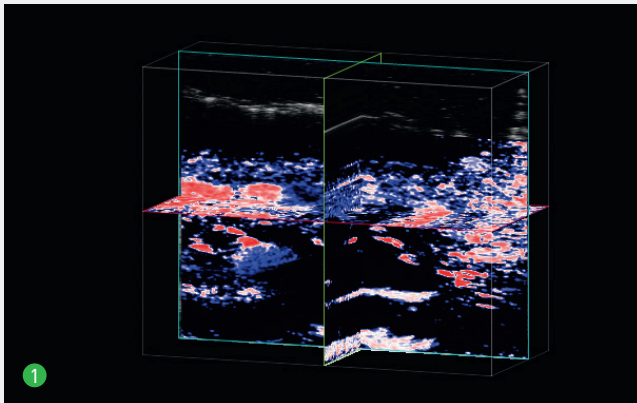


1. From the moment Granulox® is sprayed, the highly purified haemoglobin starts to bind oxygen from the environment. Oxygen loaded haemoglobin diffuses through the wound exudate<sup>11</sup>.

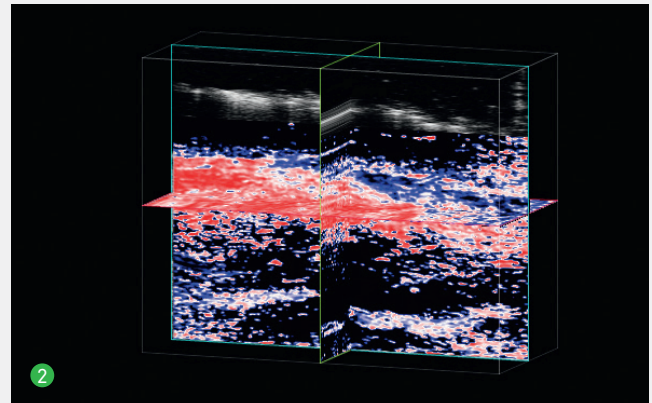


2. Due to the concentration gradient oxygen is released and the haemoglobin molecule is available to bind oxygen again<sup>11</sup>. The reversible oxygen binding property of hemoglobin means each molecule can contribute to multiple cycles of oxygen binding and release<sup>12</sup>.

## Granulox® increases wound oxygenation\*



1. Before Granulox®:  
The majority of the area is blue, indicating low oxygenation.



2. 20 minutes after Granulox®:  
Large areas of red and white are clearly recognisable, indicating high oxygenation levels throughout the wound tissue.

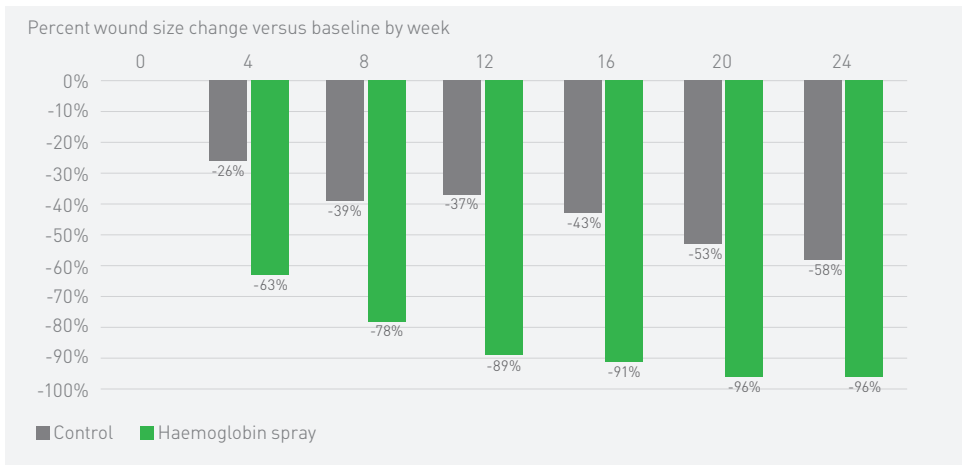
The oxygen saturation increases significantly in the tissue below the wound bed after application of Granulox®.

Photoacoustic imaging (PAI) was used to measure the local oxygen saturation ( $StO_2$ ) in leg ulcers before and after haemoglobin spray treatment<sup>13</sup>.

\*3D images of the leg ulcer with  $StO_2$ <sup>13</sup>.

# Clinical efficacy

## 1) Wound size reduction in DFU



**4 weeks** of treatment:

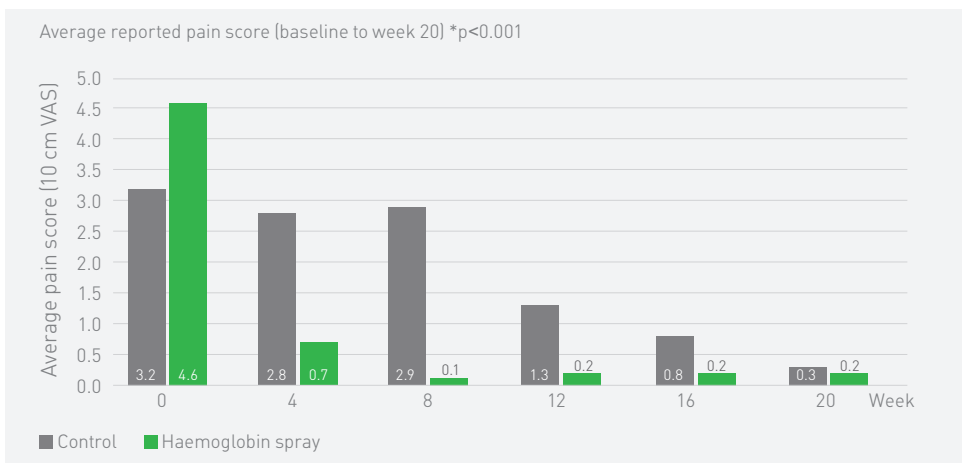
**63%** wound size reduction in Granulox® group with 5 patients fully healed

26% wound size reduction in Standard Care group with 1 patient fully healed

**Healing speed: >100%**

Wound size reduction in patients with diabetic foot ulceration receiving Standard of Care + Granulox® compared to retrospective control cohort with SoC alone (20/20 patients)<sup>1</sup>.

## 2) Pain scores in chronic wound patients



**4 weeks** of treatment:

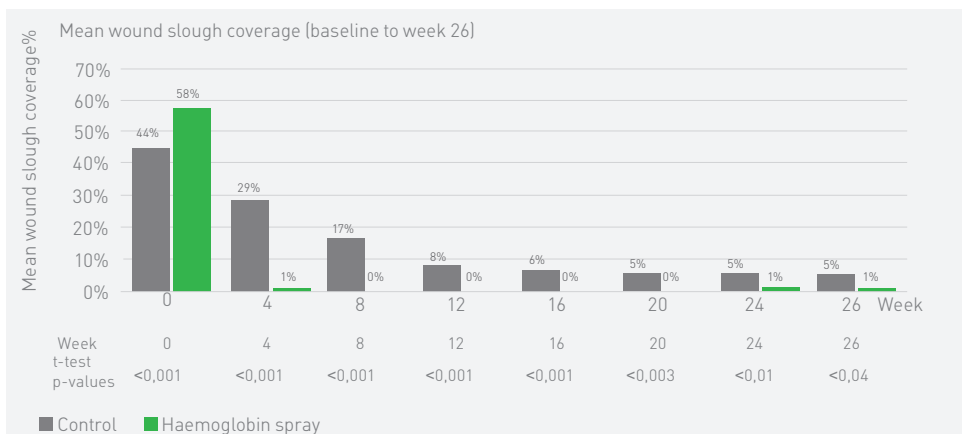
**85%** of wound pain reduction in Granulox® group

13% of wound pain reduction in Standard Care group

**> 70% advantage over Standard Care treatment**

Pain reduction in patients with chronic wounds receiving Standard of Care + Granulox® compared to retrospective control cohort with SoC alone (50/50 patients)<sup>3</sup>.

## 3) Slough coverage in wounds



**4 weeks** of treatment:

**99%** wound slough reduction in Granulox® group

33% wound slough reduction in Standard Care group

**66% advantage over Standard Care treatment**

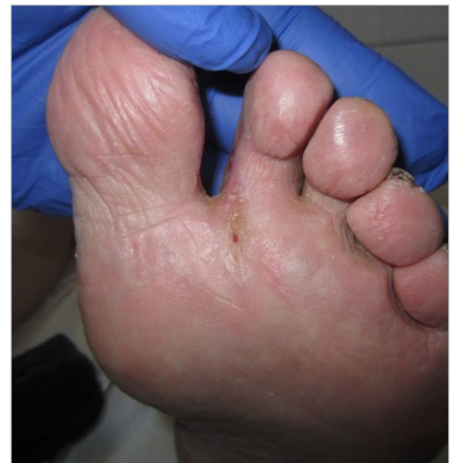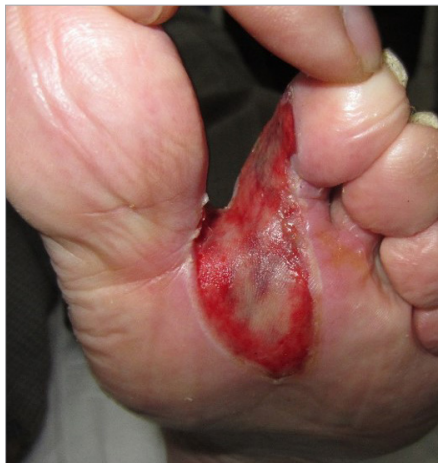Slough reduction in patients with sloughy wounds receiving Standard of Care + Granulox® compared to retrospective control cohort with SoC alone (100/100 patients)<sup>4</sup>.

## Diabetic foot ulcer<sup>14</sup>

- 85 year old male patient
- Interdigital DI-II left.
- Diabetes mellitus
- pAOD
- Arterial Hypertension
- Wound persisted for 7 months
- Treatment with: Iruxol paste,  
Alginate, Hydrocolloid,  
Polyurethan foam

**End of treatment after 73 days  
& 24 changes of bandages**

(Granulox<sup>®</sup> applied with every change)

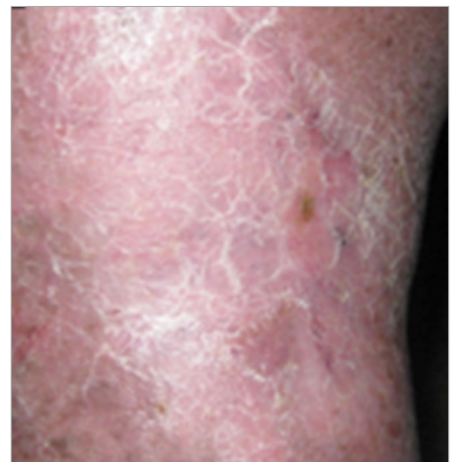
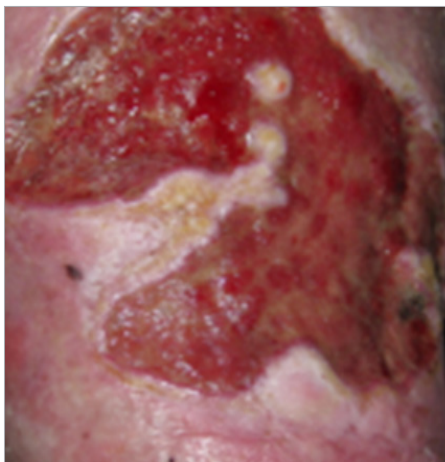


## Venous leg ulcer<sup>15</sup>

- 43 years old male patient
- Wound existed for 8 years,  
several relapses
- Budd-Chiari syndrome
- Portal hypertension
- Media sclerosis
- Start of Granulox<sup>®</sup> application:  
March 2012
- Successful end of therapy: June 2012

**Wound closure after 16 weeks of  
treatment**

(Granulox<sup>®</sup> applied every third day)

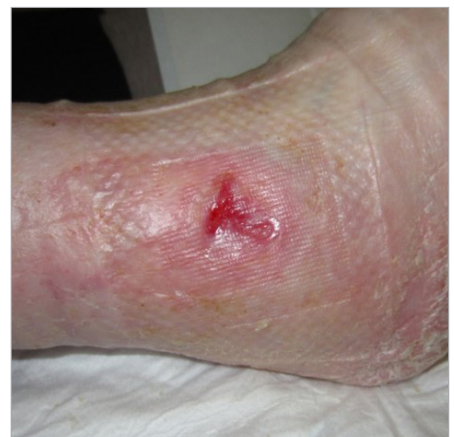
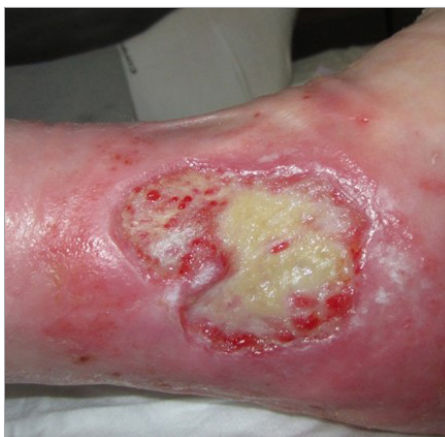
## Arterial leg ulcer<sup>14</sup>

- 85 year old female patient
- pAOD grade II-III
- Stenosis of A carotis interna  
(right)
- Multiple allergies
- Wound since 7 years

**End of treatment after 169 days  
& 50 changes of bandages**

(Granulox<sup>®</sup> applied with every change)

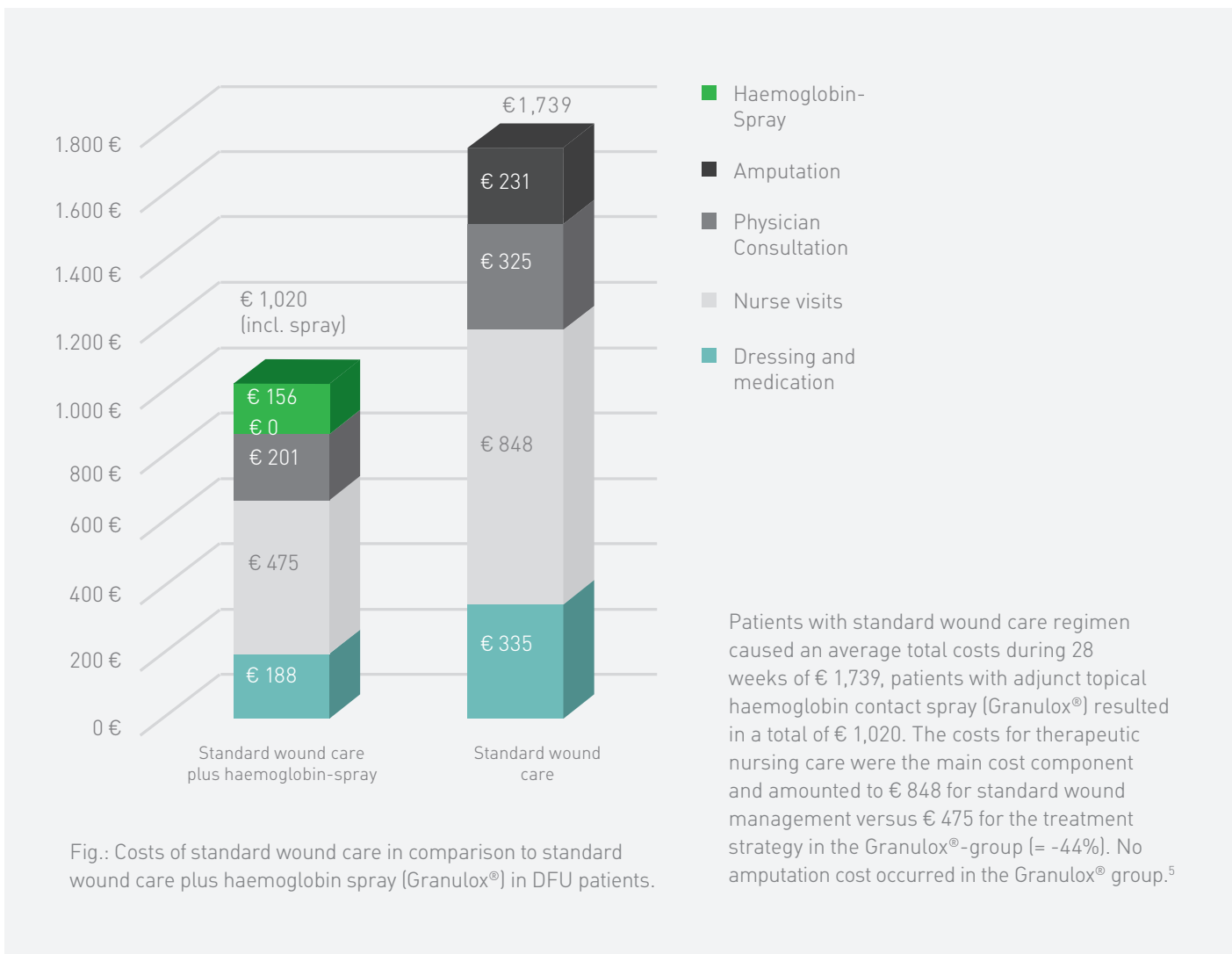


# Cost saving with Granulox®

## Faster healing saves costs

Many diabetic foot ulcers (DFU) do not respond well to wound healing treatments and cause substantial burden to healthcare resources, they often create a significant hardship for patients. When applied in addition to the standard wound care, the topical application of the haemoglobin spray Granulox® results in **an acceleration of wound healing and an improvement in wound closure**<sup>1</sup> even in stalling wounds. To illustrate the impact of

Granulox® on total treatment cost of DFU wounds from the perspective of the German statutory health insurance, the below investigation<sup>2</sup> has been undertaken: a cohort of 20 patients with chronic DFU in an acute clinical setting and treated with Granulox® was compared to a cohort of 20 patients selected from the same period of the previous year using the same protocol, retrospectively, from the same clinic<sup>1</sup>.

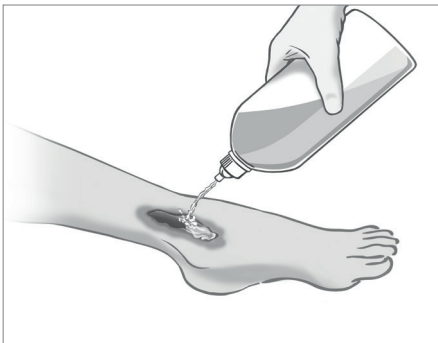

In the above cited investigation Granulox® demonstrated treatment costs in diabetic foot ulcers at **least 40% lower than with standard of care**<sup>5</sup>.

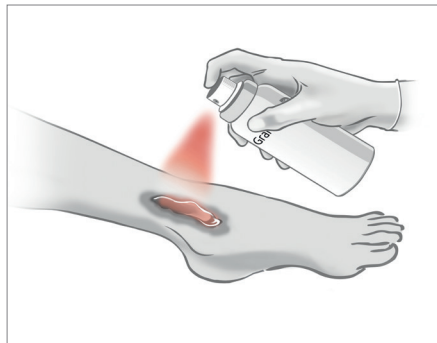
## Granulox® is easy to handle and to apply

The application of Granulox® can be adjusted to the frequency of changing the corresponding wound dressing.

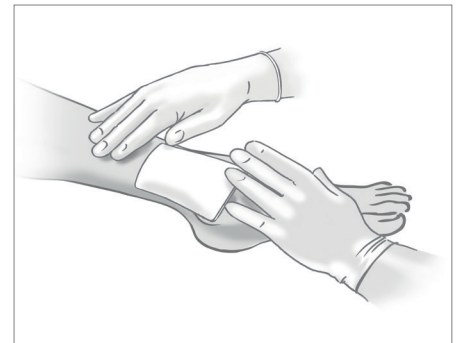
Apply Granulox® every time the dressing is changed, at least every 3 days.



1. Wound debridement and irrigation. Especially recommended HOCl/NaOCl products (e.g. Granudacyn).



2. Thin and even application of Granulox® from 5–10cm distance. 1 spray for 1 second covers a wound of 2x3cm.



3. Covering the wound with a breathable wound dressing.

## Granulox®:

- Is an innovative medical device for the treatment of chronic wounds, such as venous leg ulcer, arterial leg ulcer, mixed leg ulcer, diabetic foot ulcers, secondary healing of surgical wounds and pressure sores. Can also be used on sloughy and infected wounds.
- Provides the wound with oxygen by means of diffusion. The active substance haemoglobin supplies the base of the wound externally with oxygen. The improved oxygen supply to the base of the wound supports wound healing.

# Proving it every day

At Mölnlycke®, we deliver innovative solutions for managing wounds, improving surgical safety and efficiency and preventing pressure ulcers. Solutions that help achieve better outcomes and are backed by clinical and health-economic evidence.

In everything we do, we are guided by a single purpose: to help healthcare professionals perform at their best. And we're committed to proving it every day.

## References:

1. Hunt, SD., Elg, F. Clinical effectiveness of hemoglobin spray (Granulox®) as adjunctive therapy in the treatment of chronic diabetic foot ulcers. November 2016.
2. Hunt, SD., Elg, F. Hemoglobin spray as adjunct therapy in complex wounds: Meta-analysis versus standard care alone in pooled data by wound type across three retrospective cohort controlled evaluations. SAGE Open Medicine, 2018; 6:1-9.
3. Hunt, SD., Elg, F. The clinical effectiveness of haemoglobin spray as adjunctive therapy in the treatment of chronic wounds. Journal of Wound Care, 2017; 26(9):558-568.
4. Hunt, S., Elg F., Percival S. Assessment of clinical effectiveness of haemoglobin spray as adjunctive therapy in the treatment of sloughy wounds. Journal Wound Care. 2018 Apr; 27(4): 210-219.
5. Brüggjenjürgen, B., Hunt, SD., Eberlein, T. Wound management in diabetic foot ulcer (DFU) – incremental cost-analysis of treating diabetic neuropathic foot lesions with adjunct hemoglobin contact spray in Germany. Gesundh ökon Qual manag, 2017; 22:1-8.
6. Troxler M, Vowden K, Vowden P. Integrating adjunctive therapy into practice: The importance of recognising 'hard-to-heal' wounds. World wide wounds 2006, Available at <http://www.worldwidewounds.com/2006/december/Troxler/Integrating-Adjunctive-Therapy-Into-Practice.html>.
7. Hausier C., J. Tissue salvage by mapping of skin surface transcutaneous oxygen tension index. Arch. Surg. 1987, Oct;122(10):1128-30.
8. Dissemond, J., Kröger, K., Storck, M., Risse, A., Engels, P. Topical oxygen wound therapies for chronic wounds: a review. Journal of Wound Care, 2015, Feb, 24(2):53-63.
9. Kröger, K., Dissemond, J., Storck, M., Risse, A., Engels, P. Chronic wounds: Hypoxia prevents healing!. Wound Management 05/2012; 6(5):212-217.
10. Plot of Einstein and Smoluchowski equation for diffusion, generated by scientists at University Witten-Herdecke on request from Sangui GmbH. Data on file.
11. Petri, M., Stoffels, I., Griewank, K., Jose, J., Engels, P., Schulz, A., Pötzschke, H., Jansen, P., Schadendorf, D., Dissemond, J., Klode, J. Oxygenation Status in Chronic Leg Ulcer After Topical Hemoglobin Application May Act as a Surrogate Marker to Find the Best Treatment Strategy and to Avoid Ineffective Conservative Long-term Therapy. World Molecular Imaging Society, 2017.
12. Scholander, PF., Oxygen transport through hemoglobin solutions. Science. 1960 Feb 26;131(3400):585-90.
13. Ingo, S., Petri, M., Dissemond, J., Joachim, K. Photoacoustic tomography for non-invasive diagnostic in patients with chronic venous leg ulcers treated with hemoglobin spray – first results of a prospective clinical study. Oral presentation, EWMA 2015, London.
14. Mustafi, N. Let's see what happens: The therapeutic view beyond the horizon. Oral presentation at the the De Wu Deutscher Wundkongress, 2013, Bremen. Data on file.
15. Babadagi-Hardt, Z., Engels, P., Kanya, S. Wound management with compression therapy and topical hemoglobin solution in a patient with Budd-Chiari Syndrome. Journal of Dermatological Case Reports, 2014; 8(1):20-23.

Find out more at [www.molnlycke.ae](http://www.molnlycke.ae)

Mölnlycke Health Care AB, P. O. Box 212 565, Dubai, UAE. Phone +971 4 554 7317  
The Mölnlycke and Granulox trademarks, names and logotypes are registered globally to one or more of the Mölnlycke Health Care group of companies. © 2017 Mölnlycke Health Care AB. All rights reserved. MEAWC0036

